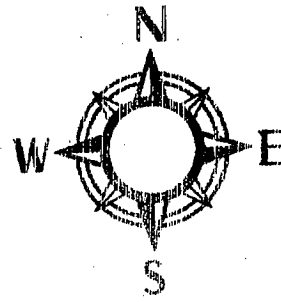


# Making an Anatomical Map



*Directions:* You will be creating an outline of a human body and diagramming and labeling the image using the following terms:

## *Cavities:*

Abdominal  
Cranial  
Pelvic  
Pleural  
Spinal  
Thoracic

## *Directional Terms:*

superior  
inferior  
anterior  
posterior  
ventral  
dorsal  
medial  
lateral  
proximal  
distal  
superficial  
deep

## *Planes of Section:*

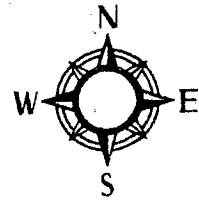
Sagittal  
Midsagittal  
Frontal (coronal)  
Transverse

*4 abdominopelvic quadrants*

## *Additional Structures:*

Mediastinum  
diaphragm

# Anatomical Map - Self-evaluation



Directions: Check off that each of the following items are included in your map. ( pt. each)

1. superior
2. inferior
3. anterior
4. posterior
5. ventral
6. dorsal
7. sagittal
8. midsagittal
9. frontal (coronal)
10. transverse
11. mediastinum
12. diaphragm
13. medial
14. lateral
15. proximal
16. distal
17. superficial
18. deep
19. abdominal
20. cranial
21. pelvic
22. spinal
23. thoracic

Total Points:

Rate your work on the following:

24. Overall quality
25. Your participation